

CLINICAL MANIFESTATIONS IN THE ANTERIOR SEGMENT OF THE EYE IN PATIENTS VISITING TERTIARY CARE HOSPITAL WITH BLUNT OCULAR TRAUMA

Sudha Madhavi KM¹, N. Maheshwara², D. M.I.S. Deepika³, Ume Salma³

Received : 30/04/2024
Received in revised form : 14/06/2024
Accepted : 29/06/2024

Keywords:

Blunt ocular Trauma(BOT), Lid ecchymosis, Road Traffic accident (RTAs), Visual impairment.

Corresponding Author:

Dr. Sudha Madhavi K M,

Email: sudhakumarkm@gmail.com

DOI: 10.47009/jamp.2024.6.3.160

Source of Support: Nil,

Conflict of Interest: None declared

Int J Acad Med Pharm
2024; 6 (3); 710-715



¹Assistant Professor, Department of Ophthalmology Chamarajanagar Institute of Medical Sciences (CIMS), Chamarajanagar, Karnataka, India

²Associate Professor, Department of Ophthalmology Chamarajanagar Institute of Medical Sciences (CIMS), Chamarajanagar, Karnataka, India

³Post Graduate Junior Resident, Department of Ophthalmology Chamarajanagar Institute of Medical Sciences (CIMS), Chamarajanagar, Karnataka, India

Abstract

Background: The study was conducted to analyze the clinicodemographic profile, various complications & management of patients presenting with definite history of recent onset of blunt ocular trauma (BOT). **Materials and Methods:** A retrospective observational study of 120 cases of definite recent onset blunt ocular trauma, from April 2022 to March 2023 presenting to casualty & outpatient department at our institution and who had documented detailed history, complete comprehensive ophthalmological examination & necessary imaging studies done were included in this study. **Result:** The study revealed that individuals aged 26-35 years (40.8%) comprised the highest proportion of blunt ocular trauma (BOT). Males were predominantly affected with male to female ratio of 2.75:1. Road traffic accidents (RTAs) were the leading cause of mode of injury (39.16%), followed by agricultural incidents (20.83%), falls (15.86%), sports-related injuries (10.83%), assaults (8.33%), household accidents (3.33%), and incidents involving crackers and blasts (1.66%). Farmers were the most affected occupational group (50.83%). Most common anterior segment manifestations included lid ecchymosis and edema (56.7%), followed by subconjunctival hemorrhage (55.8%), chemosis (34.7%), traumatic iridocyclitis (26.6%), lid laceration (20%), corneal abrasion (16.6%), traumatic cataract (8.33%), subluxation of lens (4.17%), angle recession (2.5%) & posterior dislocation of lens (0.83%). Visual acuity varied, with 53.34% exhibiting 6/6 - 6/9 vision at presentation to with perception of light and accurate projection of rays in 1.66%. **Conclusion:** Blunt ocular trauma is one of the important causes of ocular morbidity and preventable monocular blindness. This study gives insight to the importance of health education on ocular protection at work place, early diagnosis & timely intervention can reduce significant ocular morbidity & thus enhanced visual outcome in unfortunate victims.

INTRODUCTION

Ocular injury is one of the common presentation to Emergency services. Ocular trauma is a leading cause of avoidable monocular blindness and visual impairment worldwide.^[1] Ocular injury can significantly impact the future quality of life. In India, the reported incidence of ocular trauma varies from 1% to 5%.^[2,3] The global annual incidence of ocular trauma is around 55 million, of which 750,000 cases require hospitalization each year.^[4] Blunt trauma is the commonest form (54.9%) of ocular injury.^[5] Blunt trauma can result in open or closed globe injuries, with closed globe injuries

typically seen in pediatric cases, often due to sports-related to accidents or domestic mishaps. The closed globe injuries are broadly classified as contusion and lamellar lacerations. Open globe injuries can be divided into laceration and globe rupture.^[6] Injuries can result from direct blows or accidental trauma, with occupational and nonoccupational hazards also contributing, particularly in high-risk industries.

The mechanism of blunt eye trauma can be due to coup, countercoup, and anteroposterior compression or horizontal expansion of the tissue.^[7] The basic patho-physiology is that the volume of a closed space cannot be changed and therefore, when the eye is compressed along its anterior-posterior axis,

it must either expand in its equatorial plane or rupture.^[8] In most contusional injuries of the eye the anterior segment bears the brunt of both direct and indirect forces. Common symptoms at presentation include pain, loss of vision, blurring of vision, redness, increased watering, swelling around eye and bleeding.^[9] Apart from obvious ocular damage, blunt trauma may result in long-term effects like traumatic cataract and angle recession glaucoma which can make the prognosis guarded and warrant a vigilant long-term follow-up which has to be emphasized to the patients.^[10] Traumatic cataract often necessitates cataract surgery as the primary intervention.^[11] One of the common complications of trauma associated with blunt objects is the development of hyphema. Hyphema has been associated with vision-threatening complications such as increased intraocular pressure, the possibility of recurrent bleeding, and blood staining of the cornea.^[12] No matter how the injury happens, it's vital to conduct a thorough examination to identify all ocular injuries and begin appropriate treatment. Prompt detection and intervention are crucial for avoiding complications and preserving vision.

MATERIALS AND METHODS

This study is a retrospective, hospital based, observational study conducted in the outpatient Department of Ophthalmology & Casualty, Chamarajanagar Institute of Medical Sciences, Chamarajanagar, Karnataka, India. This study was done over a period of 1 year, from April 2022 to March 2023. After screening records of 292 patients having ocular injuries during above mentioned period, 120 patients with definite history of recent blunt ocular trauma due to occupational and non-occupational causes were included in the study. Sampling method used was Purposive Sampling. Consent from concerned authority was taken. The study was conducted after obtaining ethical clearance from Institutional Ethics Committee of our Institute.

Statistical Analysis: not applicable to this study

Inclusion Criteria

- The patients of all gender aged between 15-55 years.
- The patients with definite history of recent blunt ocular trauma(<1 month)
- Patients with history of blunt ocular trauma due to RTA, sports injuries, occupational and non occupational, blast injuries, assault and others.

Exclusion criteria:

- Patients who sustained serious injuries and critically ill or recumbent patients due to trauma.
- Patients with chemical, thermal and electric ocular injuries
- Patients with penetrating and perforating injuries.
- Patients with posterior segment involvement.

- Patients with other ocular pathologies and old ocular injuries of more than 1 month.
- Patients who are not willing to participate in the study.
- Patients with prior history of ocular surgeries.

A detailed history on demographic profile of patient such as age, sex, occupation and a complete history regarding blunt trauma, its mode of injury, time of presentation and any protective measures taken at the time of trauma was noted. The assessment included all patients who were subjected to detailed comprehensive ophthalmological examination of eye and its adnexal structures followed by recording of Visual acuity using Snellen's chart, slit lamp biomicroscopy of anterior segment, pupillary evaluation (reaction to light & near and presence of afferent pupillary defect), direct and indirect ophthalmoscopy for posterior segment, extraocular movements & confrontation visual field test as indicated. Intraocular pressure measurement and gonioscopy were done only in indicated patients after ruling out open globe injuries. Relevant investigations were carried out such as X ray orbits, CT or MRI imaging of orbits, fluorescein staining & Siedel's test as and when required. All cases received necessary appropriate treatment depending on the injury which included observation, conservative or surgical management. They were followed up periodically for visual outcome and ocular complications.

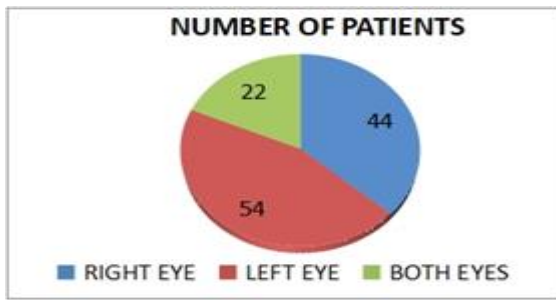
Initial evaluation also included systemic examination, presence of loss of consciousness, injury to other structures, tetanus prophylaxis status, wound contamination possibilities and previous ocular surgery.

RESULTS

Blunt ocular trauma emerged as the most common type of ocular injury in our records review of 292 patients. It constituted 41.1% of the ocular injuries.

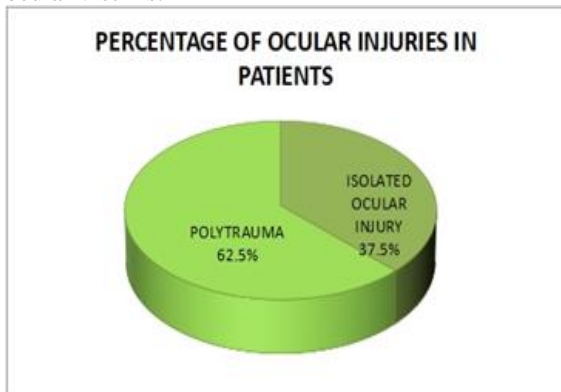
[Table 1] shows age distribution of blunt ocular trauma. It shows that among the age groups, individuals aged 26-35 years were the most affected, representing 40.8% of the total cases, followed by those aged 15- 25 (24.16%), 36-45 (19.16%), and 46-55(15.83%). Mean age of presentation was 33.1 years.

[Table 2] gives Gender-wise distribution. Males accounted for the majority of cases (88patients), comprising 73.33% of the total, while females (32patients) constituted 26.67%. The male to female ratio was 2.75:1.



Graph 1: Ocular Involvement

[Graph 1] shows right eye involvement in 44, left eye in 54 and both eyes involvement in 22 blunt ocular victims.

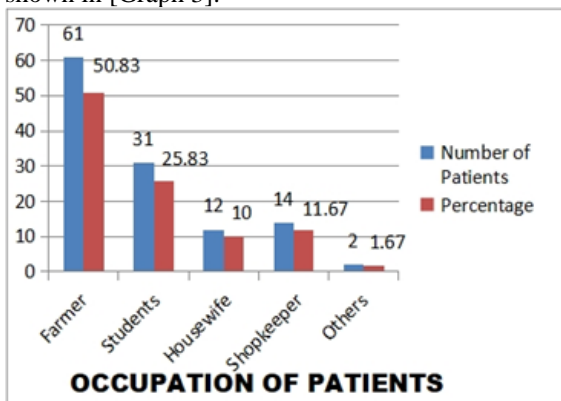


Graph 2: Percentage of isolated ocular injury versus polytrauma

Isolated ocular injury was seen in 45 (37.5%) and associated with other injuries in 75 patients (62.5%) as shown above in [Graph 2].

[Table 3] shows mode of injury of blunt ocular trauma. Road traffic accidents (RTAs) emerged as the primary mode of injury, accounting for 39.16% of cases, followed by agricultural incidents (20.83%), falls (15.86%), sports-related injuries (10.83%), physical assaults (8.33%), household accidents (3.33%), and incidents involving crackers and blasts (1.66%).

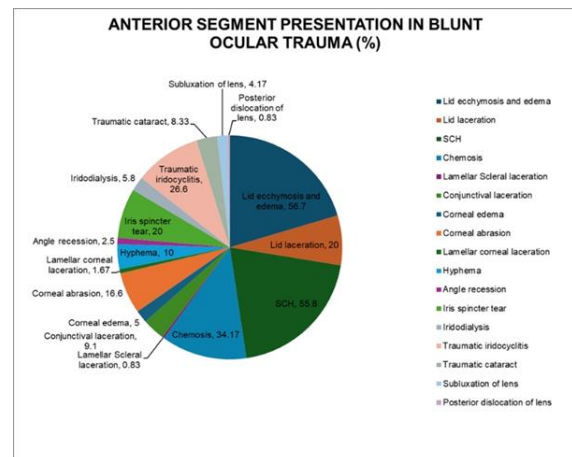
Notably, farmers were the largest occupational group affected, comprising 50.83% of cases, followed by students (25.83%), shopkeepers (11.67%), housewives (10%), and others (1.67%) as shown in [Graph 3].



Graph 3: occupational distribution of blunt ocular trauma patients

Visual acuity varied, with a significant proportion of patients exhibiting 6/6 - 6/9 vision (53.34%), followed by 6/12 - 6/24 (28.33%), 6/36 - 6/60 (11.67%), CF - HM+ (5%) and PL+ (1.66%). 28.33% of patients had visual impairment and 3.33% had blindness at initial presentation. [Table 4] shows visual acuity of patients at presentation.

Anterior segment manifestations were diverse, with lid ecchymosis and edema (56.7%), subconjunctival hemorrhage (55.8%), lid laceration (20%), chemosis (34.17%), corneal abrasion (16.6%), traumatic iridocyclitis (26.6%), and traumatic cataract (8.33%) being notable presentations as shown below in [Graph 4].



Graph 4: various presentations observed in anterior segment blunt ocular trauma

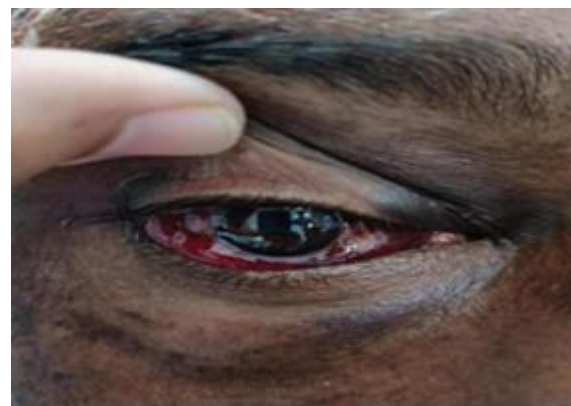

Figure 1: Subconjunctival haemorrhage

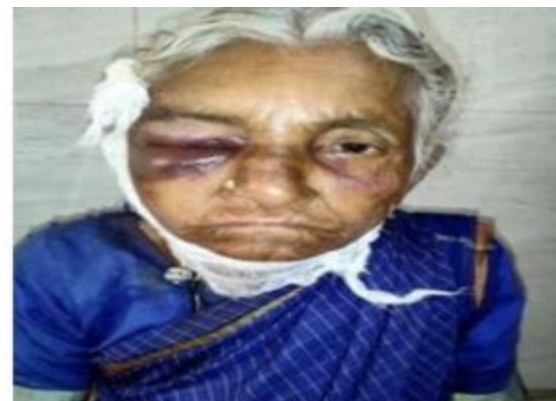

Figure 2: Lid ecchymosis with lid edema

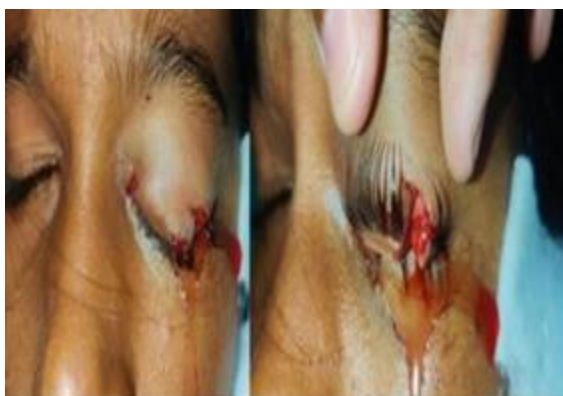

Figure 3: Lid laceration

Table 1: Age distribution of blunt ocular trauma

Sl No	Age Groups (In Years)	No. Of Patients	Percentage (%)
1	15-25	29	24.16
2	26-35	49	40.8
3	36-45	23	19.16
4	46-55	19	15.83

Table 2: Gender wise distribution of blunt ocular trauma

Sl No.	Gender	No. Of Patients	Percentage (%)
1	Male	88	73.33
2	Female	32	26.67

Table 3: Mode of blunt ocular trauma

Sl No.	Mode Of BOT	No. Of Patients	Percentage (%)
1	RTA	47	39.16
2	Fall	19	15.86
3	Agriculture	25	20.83
4	Sports	13	10.83
5	Assault	10	8.33
6	Household	4	3.33
7	Crackers and blast	2	1.66

Table 4: Visual acuity at presentation

Sl no.	Visual Acuity	No. of Patients	Percentage (%)
1	6/6 - 6/9	64	53.34
2	6/12 - 6/24	34	28.33
3	6/36 - 6/60	14	11.67
4	CF - HM+	6	5
5	PL+	2	1.66

DISCUSSION

Blunt ocular trauma is the common form of ocular trauma. It can cause trivial to sight threatening complications. Anterior segment of the eye is commonly affected. The extensive analysis on blunt ocular trauma (BOT) unveils a nuanced understanding of this complex phenomenon, providing a comprehensive depiction of its various dimensions across demographic, clinical and management parameters.

The prevalence of blunt ocular trauma in our study (41.1%) coincide with the Maurya et al,^[13] study (56.2%). Among the age groups, individuals aged 26-35years emerged as the most prominently affected cohort with mean age of 33.1 years, comprising a substantial 40.8% of the total cases, which was followed by 15-25years similar to study conducted by Parida S et al,^[14] Sahu et al,^[15] and

Maiya A et al.^[10] In Parida S et al,^[14] study the mean age affected was 32.84±21.12 years and the majority were in the age group of 21-30 years (31%), followed by 11-20 years (24.76%). This distribution suggests a higher susceptibility to ocular injuries during the prime working age years, possibly attributable to increased exposure to risk factors such as occupational hazards or outdoor activities.

In present study gender-wise analysis showed a significant male predominance, with males (88) constituting a substantial 73.33% of the total cases compared to females (32) at 26.67%, with male to female ratio of 2.75:1, corresponding to the study conducted by Jawade S et al,^[16] Maiya A et al,^[10] Sahu et al,^[15] and Makayee AA et al.^[17] Sahu et al and Makayee AA et al showed slightly higher male to female ratio of 4.5:1 and 5.25:1 respectively. This observation may reflect differences in behaviour, lifestyle, or occupational choices that predispose males to higher rates of trauma. Additionally,

societal norms and gender roles may influence the types of activities and environments in which males are more likely to engage, further increasing their risk of ocular injuries.

The study noted majority (81.67%) had unilateral blunt trauma and only 18.33% sustained bilateral trauma to the eyes. Left eye was predominantly involved (45%) which is in concordance with Maurya et al,^[13] study. Isolated ocular trauma was found in 45 patients (37.5%) while the rest majority had other associated injuries (62.5%), most common being the face followed by head injury. This observation is similar to Sahu et al study.^[15]

The mechanism of injury elucidates the diverse array of circumstances leading to blunt ocular trauma, with road traffic accidents (RTAs) emerging as the predominant cause accounting for 39.16% of cases, a finding matching to the study conducted by Singh et al,^[18] and Pai SG et al.^[8] Agricultural incidents (20.83%) and falls (15.86%) also represent significant contributors, emphasizing the importance of vehicular safety measures and fall prevention strategies in mitigating ocular trauma burden. Furthermore, understanding the specific contexts in which these injuries occur can facilitate targeted interventions and policies aimed at reducing their occurrence.

Occupational analysis highlights the vulnerability of certain professions to ocular injuries, with farmers comprising the largest occupational group affected (50.83%), a finding similar to study conducted by Sharma J et al.^[9] This finding stresses the importance of implementing safety protocols and providing protective gears in high-risk work environments to minimize the risk of ocular trauma among workers.

In current study, clinical manifestations of BOT encompassed a wide spectrum of anterior segment injuries with lid ecchymosis and edema constituting 56.7% analogous to Zigelbaum et al,^[19] study which reported most common presentation as ecchymosis and lid edema (40%). It was followed by subconjunctival hemorrhage 55.8% similar to Pai SG et al⁸ study. Total hyphema leading to sudden increase in IOP and significant decreased vision was noted in 2 out of 12 hyphema cases. In both the cases hyphema resolved with conservative management without any sequelae. Traumatic cataract was seen in 8.33% cases of which 20% presented with significant blindness on presentation warranting immediate cataract extraction. Moderate to severe subluxation of lens was found in 2 out of 5 cases and Posterior dislocation of lens in 1 blunt trauma victim on initial presentation and were referred to higher centre for lensectomy with pars plana vitrectomy. These findings bring out the diverse array of ocular injuries associated with blunt trauma and highlight the importance of comprehensive ocular evaluation and management strategies to address these varied presentations effectively.

Visual acuity assessment revealed varying degrees of visual impairment among BOT patients, with a notable proportion, 82 out of 120 exhibiting relatively preserved vision > 6/18 at presentation (68.33%). This finding is in corroboration with Sahu et al study,^[15] (69.4%) subjects had a visual acuity of >6/18, indicating no visual impairment following ocular trauma. However, a significant number of patients presented with impaired vision (28.33%) of which majority improved with appropriate treatment at 1 month follow up. The potential impact of ocular trauma on visual outcomes necessitates the importance of timely intervention to prevent permanent vision loss.

Only 30% of total traumatic cataract cases showed early evidence of lens opacity on periodic follow up and were advised observation where the rest required cataract extraction subsequently. 1 out of 3 cases of angle recession developed raise in IOP in subsequent follow up visits. There were no other significant major complications noted on follow ups.

In present study we observed that very few had some type of protection used against injury sustained at work place or in non-occupational exposure. Most of the patients had resolution of injuries with observation and conservative management.

CONCLUSION

Blunt ocular trauma involving anterior segment of eye is a common presentation. Young adult males who are frequent bread winners of the family are increasing susceptible. Monocular affection is common. RTAs stand out as the most common mode of injury. Isolated ocular injury or polytrauma are frequently observed. Those not taking any kind of safety measures in high-risk work environments are more prone. Visual acuity is often preserved with favourable prognosis in anterior segment blunt trauma. Despite favourable prognosis, need for comprehensive ocular evaluation and timely intervention strategies to address the varied presentations effectively to prevent blinding sequelae this condition can be considered as an ophthalmic emergency. Emphasis on educating the importance of wearing eye protection at work places and better vehicular safety measures can reduce this ocular mishap. High degree of vigilance and proactive management can improve the visual outcome in blunt ocular trauma victims.

REFERENCES

1. Mccarty CA, Fu CL, Taylor HR. Epidemiology of ocular trauma in Australia. *Ophthalmology*. 1999;106(9):1847–52.
2. Shukla B, Agarwal R, Shukla D, Seen S. Systematic analysis of ocular trauma by a new proposed ocular trauma classification. *Indian J Ophthalmol*. 2017;65(8):719–22.
3. Katz J, Tielsch JM. Lifetime prevalence of ocular injuries from the Baltimore eye survey. *Arch Ophthalmol*. 1993;111(11):1564–8.

4. Shukla B. Epidemiology of ocular trauma. In Shukla B, Natarajan S, editors. *Management of Ocular Trauma*. 1st ed. Delhi: Meenakshi Printers; 2005. p. 3-4.
5. Koval R, Teller J, Belkin M, Romem M, Yanko L, Savir H. The Israeli Ocular injury study: A nationwide collaborative study. *Arch Ophthalmol*. 1988;106(6):776-80.
6. Mutie D, Mwangi N. Assessing an eye injury patient. *Community Eye Health*. 2015;28(91):46-8. [PMC free article] [PubMed]
7. Mohseni M, Blair K, Gurnani B, Bragg BN. Blunt Eye Trauma [Internet]. PubMed. Treasure Island (FL): StatPearls Publishing; 2023. Available from: <https://pubmed.ncbi.nlm.nih.gov/29261988/>
8. Pai SG. A clinical study of blunt ocular trauma in a tertiary care centre [Internet]. 2013 [cited 2024 Apr 30]. Available from: <https://www.ojhas.org/issue46/2013-2-10.html>
9. Sharma J. [cited 2023 Dec 3]. Available from: https://www.worldwidejournals.com/international-journal-of-scientific-research%28IJSR%29/recent_issues_pdf/2018/January/January_2018_151480829840.pdf
10. Maiya AS, Dharmesh AM, Jayaram R. Clinical profile of ocular blunt trauma in a rural hospital. *J Clin Ophthalmol Res*. 2018 Jan-Apr;6(1):3-7. doi: 10.4103/23203897.223566
11. Pradeep TG, Honniganur DR. Anterior segment trauma: the fundamentals of management [Internet]. IntechOpen; 2022 [cited 2023 Dec 3]. Available from: <https://www.intechopen.com/chapters/80389>
12. Selma MESEN & et al. Anterior segment OCT is useful as a non-invasive imaging modality in blunt trauma patients. •The development of hyphema in ocular blunt trauma patients may result in changes in anatomical features. •Iris stroma thickness can be affected even by b, et al. Comparison of both eyes anterior segment structures of patients with unilateral blunt trauma [Internet]. Elsevier; 2023 [cited 2024 May 1]. Available from: <https://www.sciencedirect.com/science/article/abs/pii/S1572100023002697>
13. Maurya RP, Singh VP, Gautam S, Asha, Kumar A, Mishra CP, et al. Study of epidemiology, clinical profile, visual outcome and prognostic factors of blunt ocular trauma in a teaching hospital. *Indian Journal of Clinical and Experimental Ophthalmology* [Internet]. 2022 Dec 15 [cited 2023 Dec 3];8(4):458-67. Available from: <https://www.ijceo.org/article-details/18011>.
14. Parida S, Dash S, Sen S. A clinical-epidemiological study on blunt ocular trauma and its visual outcome in a tertiary care hospital of Eastern India. [Internet]. [cited 2024 Jun 27]. Available from: <https://sjhresearchafrica.org/index.php/public-html/article/view/1021>
15. Sahu SK, Radhakrishnan RV, Mohanty CR, Parija S, Palanisamy S, Mishra P, Sadangi D. Pattern and clinical profile of patients with ocular trauma presenting to the emergency department of a teaching hospital in India: A prospective observational study. *Turkish journal of emergency medicine*. 2024 Apr 1;24(2):90-6
16. Jawade S, Dagwar R, Chauhan R. Clinical Profile and Visual Outcome of Blunt Ocular Trauma in a Tertiary Care Centre of Central India: A Prospective Study. *International Journal of Medical Science and Clinical Invention*. 2020 Nov 3;7(11):5063-9.
17. Makayee AA, Aziz A, Hassan S. A PROSPECTIVE STUDY OF ANALYSIS OF OCULAR MANIFESTATIONS OF BLUNT TRAUMA TO THE EYE.
18. Evaluation of Clinical Profile of Blunt Ocular Trauma and Its Management: A Prospective Study Priyanka Singh^{1*}, Pankaj Kushwaha², Bharti Badlani³, Sowmya Iyer⁴.
19. Zigelbaum BM, Tostanoski JR, Kerner DJ, Hersh PS. Urban eye trauma. A one-year prospective study. *Ophthalmology*. 1993 Jun;100(6):851-856.